

**Hitachi Real-time Tissue  
Elastography:  
Publications & International  
Communications  
Clinical Abstracts**



**HI-RTE**

Hitachi Real-time Tissue Elastography

**Hitachi Real-time Tissue Elastography; applications for Thyroid  
and Cervical Lymph Nodes**

## REAL-TIME ULTRASOUND ELASTOGRAPHY IN THE DIAGNOSIS AND DIFFERENTIAL DIAGNOSIS OF SUBACUTE THYROIDITIS

Ping Xie MD, Ying Xiao MD, Fang Liu MD

### Purpose:

To assess the value of real-time sonographic (US) elastography in the diagnosis of subacute thyroiditis (SAT).

### Methods:

This study included 29 lesions from 20 patients with SAT, 33 nodules from 24 patients with multinodular goiter, and 27 nodules from 23 patients with thyroid cancer. Eighty-nine lesions in these patients were examined by grayscale US and real-time US elastography. An elasticity score (ES), based on four classes of tissue stiffness (class 1 for soft lesions; class 2 and 3 for lesions intermediate in stiffness; class 4 for inelastic lesions), was introduced. The distribution of ESs for SAT and multinodular goiter or thyroid cancer was compared. Also, the correlation between serum-free thyroxine (FT4) concentrations and ESs for lesions in patients with SAT was analyzed.

### Results:

Nineteen of 29 SAT lesions had an ES of 3; the rest had an ES of 4. Of 33 multinodular goiter nodules, 5 had an ES of 1, 23 had an ES of 2, and 5 had an ES of 3. Eleven of 27 malignant thyroid nodules had an ES of 3; 15 had an ES of 4, and 1 had an ES of 2. In the distribution of ESs, there was a statistically significant difference between SAT lesions and multinodular goiter nodules ( $p < 0.05$ ), but there was no significant difference between SAT lesions and malignant nodules ( $p > 0.05$ ). No correlation existed between serum FT4 concentrations and ESs for the lesions in patients with SAT ( $p > 0.05$ ).

### Conclusions:

Real-time US elastography does not provide conclusive information in the diagnosis and differential diagnosis of SAT due to its inability to distinguish between SAT and thyroid cancer.

*J Clin Ultrasound. 2011 Jun 14. doi: 10.1002/jcu.20850. [Epub ahead of print]*

---

## COMPUTER-AIDED DIAGNOSIS OF ULTRASOUND ELASTOGRAPHY FOR CLASSIFICATION OF BENIGN AND MALIGNANT THYROID NODULES

Eung Tae Kim MD Jeong Seon Park MD Kwang Gi Kim PhD Soo-Yeon Kim MD

### PURPOSE

To evaluate the computer-aided diagnosis (CAD) of US elastography for classification of benign and malignant thyroid nodules

### METHOD AND MATERIALS

Between October 2008 and February 2010, real-time thyroid US elastography was performed in 488 patients who had scheduled for US-guided fine needle aspiration. We included consecutive patients who had thyroid nodules with surgically proven histopathology ( $n=77$ ), or had at least twice results of benign thyroid cytology ( $n=146$ ). Finally, we included 223 patients (M: F=27:196; mean age, 50.8 years) with 230 thyroid nodules (89 malignant, 141 benign). Two radiologists retrospectively reviewed elastogram in consensus and assigned elasticity score from 1 to 5. For each representative elasticity image, ROI was drawn around the mass margin by another radiologist and a score for each pixel was assigned from 0 for the greatest strain to 255 for no strain. Elasticity features—mean hue histogram

value (MHHV), skewness, kurtosis, difference histogram variation, edge density, and run length—were computed to evaluate the findings of benign and malignant nodules. Best classifiers were evaluated by using forward logistic regression analysis. Receiver operating characteristic (ROC) analysis was used to evaluate diagnostic performances and the area under the curve (AUC) was compared between CAD and elasticity scores.

#### RESULTS

The AUC values of the CAD and elasticity scores were 0.95 and 0.91, respectively ( $p = 0.10$ ). The sensitivity, specificity, positive and negative predictive values were 93%, 83%, 78%, and 95% for computer-assisted classifiers, and 92%, 81%, 75%, and 94% for elasticity scores at the cut off value between 2 and 3.

#### CONCLUSION

CAD of US elasticity images has at least equal diagnostic performance compared to radiologist's elasticity-scoring in the classification of benign and malignant thyroid nodules.

#### CLINICAL RELEVANCE/APPLICATION

Computer-aided analysis of US elasticity images has the potential to aid in the classification of benign and malignant thyroid nodules.

*Radiological Society of North America 96<sup>th</sup> Scientific Assembly and Annual Meeting 2010, November 28<sup>th</sup> - December 2<sup>nd</sup>, Chicago*

---

### **ELASTOGRAPHY CAD APPLICATION EQUALS RADIOLOGIST INTERPRETATION**

By: Brian Casey, AuntMinnie.com staff writer  
November 12, 2010

In a positive early finding, South Korean researchers found that the use of a computer-aided detection (CAD) algorithm to generate ultrasound elasticity scores in thyroid scans worked as well as radiologists generating the scores on their own.

The radiologists used real-time thyroid elastography to examine 488 patients scheduled for ultrasound-guided fine-needle aspiration. Two radiologists reviewed elastograms in consensus and assigned elasticity scores from 1 to 5.

Then, researchers drew a region of interest around each mass margin and assigned scores from 0 for greatest strain to 255 for no strain for each pixel. Elasticity features such as mean hue histogram value and difference in histogram variation were computed to evaluate findings of benign and malignant nodules. Receiver operator characteristics (ROC) analysis was used to evaluate diagnostic performance, and area under the curve (AUC) was compared between CAD and radiologist-generated elasticity scores.

The researchers found that the AUC value of the CAD algorithm was 0.95, compared to 0.91 for the radiologist-generated scores, a variation that had no statistical significance ( $p = 0.10$ ). Computer-assisted classifiers produced a sensitivity of 93%, compared to 92% for the radiologist-generated scores, while specificity stood at 83% for CAD versus 81% for the radiologists.

The researchers concluded that elastography CAD has the potential to aid the interpretation of ultrasound thyroid scans by classifying malignant and benign nodules.

---

## **CONVENTIONAL ULTRASONOGRAPHY (CUS) AND ULTRASOUND ELASTOGRAPHY (USE): COMBINED SCORING FOR THE THYROID NODULES WITH INCONCLUSIVE CYTOLOGY**

Soo-Yeon Kim MD Weekeyoung Kim Jeong Seon Park MD

### **PURPOSE**

To determine the usefulness of combined scoring using CUS and USE in thyroid nodules with inconclusive cytology for differentiating malignant from benign lesions, with pathologic diagnosis as the reference standard.

### **METHOD AND MATERIALS**

We retrospectively reviewed our institutional database of preoperative USE for thyroid glands (n=227) and included consecutive data of 37 (19 benign; 18 malignant) nodules of 37 patients (F: M=31: 6; mean age, 52.1 years) who were diagnosed with inconclusive cytology by means of fine-needle aspiration biopsy and underwent subsequent surgery. Inconclusive cytology was defined as the cytologic results without definite diagnosis between malignant and benign cytology. CUS results were divided into three categories; benign (score 1), indeterminate (score 2), and malignancy (score 3). The elasticity (E) score was assigned from 1 to 5. Combined score was calculated by sum of two scores. The scores of malignant vs. benign thyroid nodules were compared by using the Student t-test. ROC curve analysis was performed and the area under the curve (AUC) of each scoring system was compared.

### **RESULTS**

The mean US score, E score and combined scores were significantly higher in the malignant nodules compared to benign nodules (P<.001). The AUC of US score, E score and combined score were 0.773, 0.865 and 0.880, respectively. The AUC of combined score was significantly higher than US score (p=0.049). There was no benign pathology in the cases of combined score >6 (n=8) and no malignancy in the cases of combined score <4 (n=3).

### **CONCLUSION**

For the differential diagnosis of thyroid nodules with inconclusive cytology, combined CUS and USE would be useful.

### **CLINICAL RELEVANCE/APPLICATION**

Combined CUS and USE may be helpful in the differential diagnosis of thyroid nodules with inconclusive cytology.

*Radiological Society of North America 96<sup>th</sup> Scientific Assembly and Annual Meeting 2010, November 28<sup>th</sup> - December 2<sup>nd</sup>, Chicago*

---

## **EFFICACY OF THYROID ELASTOGRAPHY IN DIFFERENTIAL DIAGNOSIS OF SMALL <1 CM THYROID NODULES**

Manjiri Dighe MD

### **PURPOSE**

To evaluate utility of thyroid elastography using in-vivo compression in differential diagnosis of small <1 cm thyroid nodules.

### **METHOD AND MATERIALS**

A study was conducted, after HSD approval, at our institution to perform elastography in all thyroid FNA patients. Elastography data were acquired with in-vivo compression using the Hitachi EUB-5500 machine prior to the FNA. Elastography images were generated off-line. A metric, called elasticity contrast index (ECI), was computed to quantify the elasticity contrast between the nodule and its surrounding normal tissue. A total of 37 nodules smaller than 1 cm in the transverse dimension were included. One patient had 2 nodules that were smaller than 1 cm. Retrospective analysis was performed on these 37 small nodules and elastography results were compared to FNA and/or histopathology results.

### **RESULTS**

30-6-11

For all cases, thyroid nodule(s) could be distinguished from the surroundings in elasticity images. One nodule was excluded due to inadequate FNA results. A total of 8 malignant lesions were seen in the study population with the rest (28) being benign. Using a cut-off of 3.6, ECI was able to diagnose all malignant lesions. 11 benign lesions had an ECI = or > 3.6 while 17 benign lesions had ECI < 3.6. The ECI cut-off of 3.6 yielded a sensitivity of 100% and specificity of 60.71% ( $p = 0.0002$ ).

#### CONCLUSION

Our study indicates that thyroid elastography using in-vivo compression is effective in differential diagnosis of small <1 cm thyroid nodules. In addition, using thyroid elastography with internal compression, 47% of FNA on small < 1cm nodules could be avoided leading to more efficient utilization of health care resources.

#### CLINICAL RELEVANCE/APPLICATION

Thyroid elastography using in-vivo compression shows promise in diagnosing small < 1cm malignant lesions non-invasively or avoiding biopsy in benign lesions

*Radiological Society of North America 96<sup>th</sup> Scientific Assembly and Annual Meeting 2010, November 28<sup>th</sup> - December 2<sup>nd</sup>, Chicago*

---

### **OBJECTIVE ULTRASOUND ELASTOGRAPHY SCORING ON THYROID NODULES**

Yongmin Kim PhD, Si Luo, Manjiri Dighe MD, Dong-Jun Lim MD

#### PURPOSE

To objectively derive the elasticity score for differential diagnosis of thyroid nodules using ultrasound elastography.

#### METHOD AND MATERIALS

Elastography data from 82 patients (92 nodules) referred for an FNA biopsy were used for this retrospective study. An IRB approval from the University of Washington was obtained. Elastography was performed prior to the FNA using a clinical ultrasound machine, Hitachi Hi Vision 5500. No external compression was applied since carotid artery pulsation was used as the compression source. Instead of assigning a score of 1~5 by visually inspecting the elastography images to make a diagnosis, the spatial distribution of a strain image was analyzed by calculating the occurrence rate of different combinations of strain values. A metric, called elasticity contrast index (ECI), was then computed to quantify the difference in stiffness between the nodule and its surrounding normal tissue. A larger ECI value suggests a stiffer nodule, thus indicating the increased likelihood of being malignant.

#### RESULTS

The mean nodule size was 2.1 × 1.6 × 1.9 cm (ranging from 0.5 × 0.6 × 0.6 cm to 4.1 × 2.3 × 3.5 cm). 21 out of 92 were smaller than 1 cm. The mean ECI ( $n=12$ ,  $6.32 \pm 2.25$ ) of malignant nodules was significantly higher than that of benign nodules ( $n=80$ ,  $3.39 \pm 1.58$ ) ( $p=0.0008$ ), indicating that malignant nodules are stiffer than benign nodules compared to the surrounding normal tissue. Using a cut-off value of 3.85, all 12 malignant nodules could be detected, leading to the sensitivity, specificity, positive predictive value and negative predictive value of 100%, 73.8%, 36.4% and 100%, respectively.

#### CONCLUSION

We have developed an objective method to derive the ultrasound elastography score. For most US elastography studies, the stiffness of a nodule is inferred by visually inspecting the pseudo-color pattern in the strain images. This approach tends to be subjective and suffers from intra and interobserver variability. Utilizing the strain distribution information, the elasticity contrast index (ECI) was effective in quantifying the elasticity difference between a nodule and its surrounding tissue. This method is also applicable in the thyroid elastography using external compression.

#### CLINICAL RELEVANCE/APPLICATION

The quantification of elasticity scores could be of benefit in reducing the intra and interobserver variability and the amount of training required for interpreting the ultrasound elastography images.

## **ULTRASOUND ELASTOGRAPHY COULD AVOID FUTILE THYROID BIOPSIES**

Elastography has been drawing interest as a means to use ultrasound to detect pathology by detecting signs of tissue stiffness. In this study, researchers from the University of Washington in Seattle will discuss their method to use elastography on thyroid nodules.

Thyroid nodules are a common medical problem, but only 5% are malignant. Biopsy is typically conducted with fine-needle aspiration (FNA); some 300,000 thyroid biopsies are performed each year in the U.S., with 70% of these proving benign.

For the past five years, the authors have been working on a thyroid elastography technique using internal compression provided by the carotid artery. Internal compression has a couple of advantages over external compression, they believe: It reduces operator dependency and the strain estimation error can be minimized, making the technique more repeatable and accurate.

The researchers examined the technique in a population of 82 patients with 92 nodules who were referred for FNA biopsy. Elastography was performed by a commercially available ultrasound machine (HI Vision 5500, Hitachi Medical Systems America, Twinsburg, OH).

Rather than assigning tissue scores based on visual inspection, the researchers calculated an elasticity contrast index (ECI) to quantify the difference in stiffness between a nodule and its surrounding normal tissue. A larger ECI value indicates a stiffer nodule and, thus, an increased chance of malignancy.

The researchers found that the 12 malignant nodules in their patient population had a mean ECI of  $6.32 \pm 2.25$ , significantly higher than that of the 80 benign nodules, which had a mean ECI of  $3.39 \pm 1.58$  ( $p = 0.0008$ ). This indicates that malignant nodules are stiffer than benign nodules compared with surrounding normal tissue.

Using a cut-off ECI value of 3.85 to indicate malignancy, all 12 malignant nodules could be detected, leading to a sensitivity of 100%, specificity of 73.8%, positive predictive value of 36.4%, and negative predictive value of 100%.

The paper will be presented by Yongmin Kim, PhD.

By: Brian Casey, AuntMinnie.com staff writer  
November 12, 2010

---

## **DIFFERENTIAL DIAGNOSIS OF SMALL SINGLE SOLID THYROID NODULES USING REAL-TIME ULTRASOUND ELASTOGRAPHY**

Y WANG1\*, H-J DAN2\*, H-Y DAN3, T LI2 AND B HU1

1Department of Ultrasound in Medicine, The Sixth People's Hospital Affiliated to Shanghai Jiao Tong University, Shanghai, China; 2Department of Ultrasound, and 3Department of Haematology, The Second Hospital of Hebei Medical University, Shijiazhuang, Hebei, China

In this prospective study, the diagnostic value of real-time ultrasound elastography (USE) was evaluated in 51 consecutive patients referred for surgical treatment with single solid thyroid nodules < 10 mm in maximum diameter with an indeterminate result on B-mode and colour Doppler ultrasonography. Ultrasonographic results were compared with histopathological data. Nineteen

follicular adenomas and 32 papillary thyroid microcarcinomas (PTMCs) were observed. A real-time USE score of 4 – 5 diagnosed PTMCs with a sensitivity of 90.63%, a specificity of 89.47% and an accuracy of 90.20%. The positive and negative predictive values were 93.55% and 85.00%, respectively. It is concluded that real-time USE is a promising imaging technique that could assist in the differential diagnosis of single solid thyroid nodules < 10 mm in maximum diameter that give indeterminate results on conventional ultrasound.

*The Journal of International Medical Research 2010; 38: 466 – 472*

---

## **REAL-TIME ELASTOGRAPHY FOR THE DIFFERENTIATION OF BENIGN AND MALIGNANT THYROID NODULES: A META-ANALYSIS**

Jörg Bojunga,<sup>1</sup> Eva Herrmann,<sup>2</sup> Gesine Meyer,<sup>1</sup> Sonja Weber,<sup>1</sup> Stefan Zeuzem,<sup>1</sup> and Mireen Friedrich-Rust<sup>1</sup>

<sup>1</sup>Department of Internal Medicine I, J.W. Goethe-University Hospital, Frankfurt, Germany.

<sup>2</sup>Faculty of Medicine, Institute of Biostatistics and Mathematical Modelling, J.W. Goethe-University, Frankfurt, Germany.

**Background:** Work-up of thyroid nodules remains challenging. Fine-needle aspiration (FNA) has been shown to be the most cost-effective way to select patients for surgery with sensitivities of 54%–90% and specificities of 60%–96% for the detection of malignant lesions. Ultrasound-based real-time elastography (RTE) enables the determination of tissue elasticity and has shown promising results for the differentiation of thyroid nodules. A meta-analysis was performed to assess the overall performance of RTE for the differentiation of thyroid nodules.

**Methods:** Literature databases were searched. The inclusion criteria for studies were the use of FNA cytology histopathology of surgical specimens as the diagnostic reference standard and assessment of sensitivity and specificity of RTE. The meta-analysis was performed using an inverse variance method and the Der Simonian and Laird Random effect estimator in case of established heterogeneity.

**Results:** Eight studies that included a total of 639 thyroid nodules were analyzed. The overall mean sensitivity and specificity for the diagnosis of malignant thyroid nodules by RTE of the eight studies was 92% confidence interval 88–96 and 90% confidence interval 85–95, respectively. A significant heterogeneity was found for specificity of the different studies.

**Conclusions:** RTE has a high sensitivity and specificity in the evaluation of thyroid nodules. This technique might be useful in conjunction or even instead of FNA to select patients with thyroid nodules for surgery.

*Thyroid. 2010 Oct;20(10):1145-50.*

---

## **REAL-TIME ULTRASOUND ELASTOGRAPHY—A NONINVASIVE DIAGNOSTIC PROCEDURE FOR EVALUATING DOMINANT THYROID NODULES**

Christian Vorländer & Jan Wolff & Said Saalabian & Robert H. Lienenlücke & Robert A. Wahl

Purpose Ultrasound elastography (USE) is a newly developed technique for the evaluation of tissue stiffness. It is known that malignancies often show a low-strain value. So far, only limited data for thyroid nodules is available.

Methods This study included 309 prospective evaluated patients with dominant, nontoxic thyroid nodules. All patients were referred to surgery. USE was performed preoperatively. Three measuring groups were formed: hard (< 0.15), intermediate (0.16–0.3), and soft (> 0.31). The measurements

were correlated to the final histological findings.

**Results** The strain rated from 0.01 to 0.84 (mean  $0.26 \pm 0.13$ ). A total of 50 thyroid malignancies (35 papillara carcinoma, 9 medullary carcinoma, and 6 follicular carcinoma) were observed. Patients (81) were within the hard group, 35 of them (43.2%) had thyroid cancer (TC) in final histology. Out of 132 patients in the intermediate group, 15 patients had TC (11.4%). All 96 patients from the soft group showed benign histological results (NPV 100%). Seventy percent of patients with TC were within the hard group (PPV 42%). These results were highly significant ( $p < 0.001$ ). Coarse calcifications and cystic nodules were not connected with reliable measurements and therefore are not suitable for USE.

**Conclusion** USE is a useful adjunctive tool in the workup of thyroid nodules. A low strain value needs surgical intervention, whereas a high strain value predicts a benign histology. It might substitute fine-needle aspiration cytology in the future.

*Langenbecks Arch Surg (2010) 395:865–871*

---

## **REAL-TIME ULTRASOUND ELASTOGRAPHY — A NEW TOOL FOR DIAGNOSING THYROID NODULES**

*Małgorzata Gietka-Czernel<sup>1</sup>, Magdalena Kochman<sup>1</sup>, Karolina Bujalska<sup>1</sup>,*

*Elżbieta Stachlewska-Nasfeter<sup>2</sup>, Wojciech Zgliczyński<sup>1</sup>*

*1Department of Endocrinology, The Medical Centre of Postgraduate Education, Warsaw, Poland*

*2Head and Neck Cancer Department, Maria Skłodowska-Curie Memorial Cancer Centre and Institute of Oncology, Warsaw, Poland*

**Introduction:** Real-time elastography (RTE) is a non-invasive ultrasound method of estimation of tissue stiffness by measuring the degree of local tissue displacements after a small compression. Recent data has shown its ability to differentiate benign from malignant tumours. The aim of this study was to evaluate the accuracy of RTE in the diagnosis of malignant and benign thyroid nodules.

**Material and methods:** 71 thyroid nodules in 52 patients: 42 females and 10 males aged 28–77 were examined using conventional ultrasonography (US), fine-flow CD imaging and RTE. All nodules previously underwent fine-needle aspiration biopsy (FNAB), and patients with malignant and suspicious cytological results were referred for surgery. The final diagnosis was based on FNAB results in patients with benign cytology and on the histopathology reading in those who underwent surgery. An elasticity score (ES) from 1 to 5 was determined for each nodule according to the Ueno classification.

**Results:** An elasticity score (ES) of 4 or 5 was found in 19 out of 22 (86.5%) thyroid cancers and in only 1 out of 31 (3%) benign nodules. This was strongly indicative for malignancy ( $p < 0.0001$ ) with sensitivity 86%, specificity 97%, positive predictive value (PPV) 95% and negative predictive value (NPV) 91%.

**Conclusions:** RTE is a highly sensitive and specific method of diagnosing thyroid nodules. This technique can be employed in selecting thyroid nodules for fine-needle aspiration biopsy.

*Pol J Endocrinol 2010; 61 (6): 652–657*

---

## UTILITY OF THE ULTRASOUND ELASTOGRAPHIC SYSTOLIC THYROID STIFFNESS INDEX IN REDUCING FINE-NEEDLE ASPIRATIONS.

Dighe M, Kim J, Luo S, Kim Y.

Department of Radiology, University of Washington Medical Center, Seattle, WA 98195, USA.  
dighe@u.washington.edu

### Abstract

**OBJECTIVE:** The purpose of this study was to evaluate whether ultrasound elastography performed by using carotid pulsation as a compression source and generating the systolic thyroid stiffness index (STSI) can be used as a pre-fine-needle aspiration (FNA) screening tool. **METHODS:** Ultrasound data previously acquired from 62 thyroid nodules in 59 patients who underwent a thyroid FNA were used. Pulsation from the carotid artery was used as the compression source, and the strain was calculated offline. A metric called the STSI was computed for each nodule during systole. On the basis of the derived STSI value, thyroid nodules were retrospectively classified into 2 types: I, no FNA (observation only); and II, FNA. **RESULTS:** The STSI value of malignant nodules ( $n = 12$ ) was significantly higher than that of benign nodules ( $n = 39$ ;  $P < .00002$ ). Using an STSI cutoff value of 10, 31 nodules were classified as type I, all of which were benign, whereas 20 nodules were classified as type II, 12 malignant and 8 benign, with sensitivity of 100% and specificity of 79.4%. This suggests that ultrasound elastography could have screened out 31 type I nodules, reducing the number of FNAs by 60.8%. **CONCLUSIONS:** Thyroid ultrasound elastography has the potential to substantially reduce the number of FNA biopsies by detecting type I benign nodules. Patients with suspicious type II nodules would be referred for an FNA. Future prospective studies are needed to confirm the efficacy of thyroid ultrasound elastography as a triage tool to FNA.

*J Ultrasound Med.* 2010 Apr;29(4):565-74.

---

## THYROID ELASTOGRAPHY MAY REDUCE UNNECESSARY FNA BIOPSIES

By [Erik L. Ridley](#)  
AuntMinnie staff writer  
April 21, 2010

A significant percentage of thyroid nodule fine-needle aspiration (FNA) biopsies lead to benign findings. But use of thyroid elastography may avoid the need for biopsy in many of these patients, according to research published in the April issue of the *Journal of Ultrasound in Medicine*.

A research team led by Dr. Manjiri Dighe of the University of Washington Medical Center in Seattle found that quantitative measurements generated from ultrasound elastography could be used to reliably characterize a substantial amount of benign nodules. As a result, only nodules with suspicious findings would go on to receive FNA biopsy.

"With that approach, we may be able to decrease the number of FNA biopsies by 60%," Dighe told *AuntMinnie.com*. "The ability to confidently diagnose a benign nodule is the most important benefit of elastography."

The researchers sought to determine if a systolic thyroid stiffness index (STSI) -- generated from ultrasound elastography performed by using carotid pulsation as a compression source -- could serve as a pre-FNA biopsy screening tool. They gathered ultrasound data previously acquired from 62 thyroid nodules in 59 patients who had received a thyroid FNA (*J Ultrasound Med*, April 2010, Vol. 29:4, pp. 565-574).

The ultrasound elastography studies were performed prior to the FNA procedure using a Hi Vision 5500 ultrasound scanner (Hitachi Medical Systems America, Twinsburg, OH) with a 7.5-MHz linear-

array transducer. Ten patients were excluded from the study due to inadequate FNA sample results, and one was left out due to inadequate elastography data acquisition.

The sonographers who acquired the studies had more than 10 years of ultrasound scanning experience, as well as more than two years of experience in acquiring elastographic data, according to the researchers. Ultrasound data were processed offline using an angular strain method for elastography; about 200 strain images were generated.

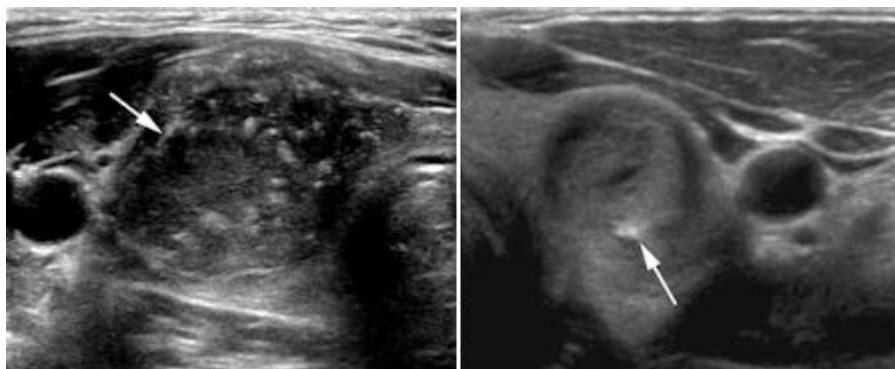
The group then calculated an STSI value by dividing the strain value near the carotid artery at systole by the corresponding strain value in the nodule. A higher STSI value suggests a stiffer thyroid and an increased likelihood of malignancy.

The nodules were classified into two FNA screening categories based on the STSI value. The first category (type I) would receive observation only and no FNA biopsy, and the second category (type II) would undergo biopsy.

The researchers determined the cutoff STSI value to differentiate the nodules based on receiver operator characteristics (ROC) analysis.

At  $18.43 \pm 5.99$ , the mean STSI for the 12 malignant nodules was significantly higher than the mean index of  $6.82 \pm 3.54$  for the 39 benign nodules ( $p = 0.00002$ ). The area under the ROC curve for diagnosing papillary carcinoma was 0.942 for distinguishing between malignant and benign nodules.

From the ROC analysis, the researchers found that a cutoff index value of 10 yielded 100% sensitivity, 79.5% specificity, 60% positive predictive value, and 100% negative predictive value.



*Left, malignant hypoechoic solid nodule with central areas of calcification and an STSI of 20.1. Right, benign hypoechoic nodule with peripheral calcifications and an index value of 5.6. Images courtesy of the Journal of Ultrasound in Medicine.*

Based on the researcher's guidelines, 60.8% of the biopsies could have been avoided.

"Only 20 (8 benign and 12 malignant) nodules that were classified as type II would have undergone an FNA," the authors wrote. "Thus, by using thyroid ultrasound elastography as a triage tool, it would be possible to limit FNAs to only type II (high probability of malignancy) nodules, thereby decreasing the percentage of benign nodules being referred for an FNA."

The authors noted that future prospective studies will be needed to confirm elastography's efficacy as a triage tool to FNA.

By [Erik L. Ridley](#)

AuntMinnie.com staff writer, April 21, 2010

## REAL-TIME ELASTOGRAPHY AND CONTRAST-ENHANCED ULTRASOUND FOR THE ASSESSMENT OF THYROID NODULES.

Friedrich-Rust M, Sperber A, Holzer K, Diener J, Grünwald F, Badenhoop K, Weber S, Kriener S, Herrmann E, Bechstein WO, Zeuzem S, Bojunga J.

Department of Internal Medicine 1, J. W. Goethe-University Hospital, Frankfurt, Germany.

**OBJECTIVE:** Work-up of thyroid nodules remains challenging. Recent technologies enable determination of tissue elasticity and perfusion using ultrasound devices. The aim of the present study was to evaluate real-time elastography (RTE) and contrast-enhanced ultrasound with Sonovue (CEUS) for the differentiation of benign and malignant thyroid nodules.

**MATERIALS AND METHODS:** Inclusion criteria were: nodules  $\geq 1$  cm, non-functioning or hypo-functioning on radionuclide scanning, and cytological/histological assessment. All patients received conventional ultrasound, RTE and CEUS. RTE was classified as: Elasticity-Score (ES)1=soft, ES2=predominantly soft, ES3=predominantly hard, ES4=hard nodule. CEUS-video clips were digitally recorded and analyzed using time-intensity-curves within selected regions-of-interest.

**RESULTS:** Fifty-three nodules in 50 patients were available for analysis. Forty-six nodules were benign on cytology/histology, 6 nodules were papillary carcinoma and one nodule was a follicular carcinoma. Nodule margin irregularity was the ultrasound pattern most predictive of malignancy with sensitivity 57% (95% confidence interval: 18-90%) and specificity 85% (71-94%  $p < 0.05$ ). When using ES3&4 for the diagnosis of malignant nodules sensitivity and specificity were 86% (42-99.7%) and 87% (75-95%), respectively ( $p = 0.0003$ ). The only malignant nodule missed with RTE was a follicular carcinoma. Sensitivity for the diagnosis of papillary carcinoma therefore was 100%. No specific CEUS pattern could be identified to differentiate between benign and malignant nodules.

**CONCLUSIONS:** RTE seems to be a useful tool in the work-up of thyroid nodules to exclude papillary thyroid cancer. However, follicular carcinoma remains a challenging problem. CEUS did not improve the characterization of thyroid nodules in this preliminary study.

*Exp Clin Endocrinol Diabetes. 2009 Oct 23. [Epub ahead of print]*

---

## USEFULNESS OF ULTRASOUND ELASTOGRAPHY IN IDENTIFYING THYROID MALIGNANCY

Dr Cristina Ghervan, Dr Dana Dumitriu, Dr Carolina Botar-Jid, Dr Sorin Dudea, Dr Valentin Munteanu, Dr Iacob Domsa, Dr Ileana Duncea, University of Medicine and Pharmacy, Romania

**Background and objective:** One of the key features of thyroid gland cancer evaluated at palpation is the degree of firmness: malignant lesions tend to be much harder than benign ones. US elastography is combining the diagnostic advantages of high-frequency US examination and the accuracy of thyroid cancer diagnosis based on the lesion's stiffness. The aim of our prospective study was to evaluate the elastographic appearance of thyroid gland tumors and to explore the sensitivity and specificity of US elastography for differential diagnosis of thyroid cancer, with histopathologic analysis as a reference standard

**Material and Methods:** A total of 34 patients were included in the study, presenting one or several suspicious thyroid nodules. Elastography was performed by the same examiner with the same settings of the machine. The nodules were classified in five classes of tissue stiffness. All the patients were operated and the results of elastography were compared with histopathologic results.

**Results:** The 34 patients had 99 thyroid nodules that were investigated. 65 were soft in elastography (score 1-3) and 34 were hard (score 4-5). At pathological exam all the 65 soft nodules were benign and from the 34 hard nodules 17 were benign and 17 malignant. In 4 patients multiple malignant nodules were found.

**Conclusion:** Elastography showed a sensitivity of 100% and a specificity of 79% in diagnosing malignant nodules. With a positive predictive value (PPV) of 50% and a negative predictive value (NPV) of 100% it seems more valuable in excluding malignancy than in affirming it.

*12<sup>th</sup> World Congress of the World Federation for Ultrasound in Medicine and Biology, 30<sup>th</sup> August – 3<sup>rd</sup> September 2009, Sydney, Australia*

## CLINICAL APPLICATION OF ULTRASOUND ELASTOGRAPHY FOR DIAGNOSIS OF PARATHYROID CARCINOMA

Mrs Hiroko Kiyomatsu, Mr Ei Ueno, Ms Eriko Tohno, Mrs Hiroko Bando, Mr Tohru Yashiro, Mr Yukio Morishita, Mr Hisato Hara  
Tsukuba University Hospital, Japan

**Background:** Preoperative evaluation is very important for the diagnosis of parathyroid carcinoma. However, fine needle aspiration cytology(FNAC) is not recommended because of its possibility of tumor implantation. So only clinical data have been considered as usable indicator of malignancy. We reported high Depth-Width(DW) ratio ( $\geq 1$ ) of a tumor is an important indicator of malignancy. Due to its high sensitivity, the specificity of DW ratio was slightly poor because large part of benign tumors sometimes showed high DW ratio. So we introduced ultrasound Elastography, in addition to the normal B-mode ultrasound evaluation including measurement of DW ratio, to improve the specificity.

**Material and Methods:** First of all, we performed B-mode ultrasound examination for patients with parathyroid enlargement and calculated its DW ratio. Malignancy was suspected for a tumor with DW ratio  $\geq 1$  or a very large tumor that its DW ratio could not be calculated. We used thyroid gland as a control tissue, and compared the elasticity between the two. We made diagnosis between benign or malignant tumors based on the elasticity of parathyroid compared to thyroid gland. The operation was performed based on the diagnosis.

**Results:** Among the four cases which were suspected of malignancy by B-mode ultrasound examination, two cases were soft and the other two cases were hard compared to thyroid gland. Pathological examination of these four cases showed that the former two cases were adenoma and the later two cases were adenocarcinoma.

**Conclusion:** Ultrasound Elastography is easy to perform and offers additional information to conventional ultrasound for parathyroid carcinoma detection.

*12<sup>th</sup> World Congress of the World Federation for Ultrasound in Medicine and Biology, 30<sup>th</sup> August – 3<sup>d</sup> September 2009, Sydney, Australia*

---

## CLINICAL EVALUATION OF ELASTOGRAPHY FOR THE DIFFERENTIAL DIAGNOSIS OF THYROID FOLLICULAR TUMORS

Nobuhiro Fukunari, Kazushige Arai, Akio Naakamura, Tomomi Yamazaki, Satoshi Sakaue, Kenji Nakano

**Purpose:** The diagnosis and management of follicular cancer of the thyroid gland remains a controversial topic. The aim of this study was to evaluate the clinical usefulness of Elastography imaging for the differential diagnosis of thyroid follicular lesions.

**Methods and Materials:** 133 follicular tumors were examined by Elastography. Papillary cancers, other types thyroid malignancies or hot nodules were excluded from this study. The images of thyroid follicular lesions were recognized as four typical patterns as follows: Pattern 1(P1): nodule is relatively homogenous and colored with light green. Pattern 2(P2): the center of nodule is colored with green and its periphery is colored with blue. Pattern 3(P3): nodule is mixed-colored with light green and red. Pattern 4(P4): the whole tumor is displayed in blue.

**Results:** All the follicular tumors were surgically and histopathologically diagnosed finally. In this series, 58 hyperplastic nodules, 33 follicular adenomas and 42 follicular cancers (28 Minimally invasive, 14 Widely invasive) were found. Of the 42 follicular cancers, 31 cases were P2, which was occupied 73.8%. Assuming Pattern 2 to be malignant and others to be benign, 87 of 91 benign tumors and 31 of 42 follicular cancers were accurately diagnosed, yielding a sensitivity of 78.8%, a specificity of 95.6%, and an accuracy of 90.2%.

**Conclusion:** Elastography can provide new useful information for the differential diagnosis of thyroid follicular tumors and has a capability to improve the diagnostic specificity and accuracy than that of our former studies of color-Doppler examination.

*12<sup>th</sup> World Congress of the World Federation for Ultrasound in Medicine and Biology, 30<sup>th</sup> August – 3<sup>d</sup> September 2009, Sydney, Australia*

---

## REAL-TIME ULTRASOUND ELASTOGRAPHY IN THE DIFFERENTIAL DIAGNOSIS OF BENIGN AND MALIGNANT THYROID NODULES

Yurong Hong, Xueming Liu, Zhiyu Li, Xiufang Zhang, Meifeng Chen, Zhiyan Luo.

**Objective.** The purpose of this study was to evaluate the diagnostic utility of real-time ultrasound elastography in differentiating benign from malignant thyroid nodules.

**Methods.** A total of 90 consecutive patients with thyroid nodules who were referred for surgical treatment were examined in this prospective study. One hundred forty-five nodules in these patients were examined by B-mode ultrasound, color Doppler ultrasound, and ultrasound elastography. The final diagnosis was obtained from histologic findings. Tissue stiffness on ultrasound elastography was scored from 1 (low stiffness over the entire nodule) to 6 (high stiffness over the entire nodule and surrounding tissue).

**Results.** On real-time ultrasound elastography, 86 of 96 benign nodules (90%) had a score of 1 to 3, whereas 43 of 49 malignant nodules (88%) had a score of 4 to 6 ( $P < .001$ ), with sensitivity of 88%, specificity of 90%, a positive predictive value of 81%, and a negative predictive value of 93%. The predictivity of ultrasound elastographic measurement was independent of the nodule size. High sensitivity (88%) and specificity (93%) were also observed in 68 nodules that had a greatest diameter of 1 cm or less.

**Conclusions.** Real-time ultrasound elastography is a promising imaging technique that is useful in the differential diagnosis of thyroid cancer.

*J Ultrasound Med 2009; 28:861–867*

---

## DIFFERENTIAL DIAGNOSIS OF BENIGN AND MALIGNANT THYROID NODULES AT ELASTOSONOGRAPHY.

Rubaltelli L, Corradin S, Dorigo A, Stabilito M, Tregnaghi A, Borsato, S, Stramare R.

Dpt. of Medical Diagnostic Sciences and Special Therapies, University of Padova.

**PURPOSE:** Ultrasound of the neck detects a large number of non-palpable thyroid nodules in the population, but it offers poor diagnostic accuracy (the presence of microcalcifications is the only statistically significant criterion indicative of malignancy). The aim of this study is to evaluate elastography, a technique which allows differentiation between pathological and normal tissue by determining its hardness and which could also prove useful in the characterisation of thyroid nodules.

**MATERIALS AND METHODS:** In this prospective study, 51 thyroid nodules in 40 consecutive patients were examined (25 women, 15 men, mean age  $\pm$  SD, 54  $\pm$  13.4). Elastosonography was performed by real-time, free-hand technique, using Logos HiVision equipment with a 10 MHz transducer and lesions were classified and scored in 4 classes of hardness. All patients were also examined by grey scale high frequency ultrasound and colour Doppler. Final diagnoses were obtained from cytological and/or histological evaluation.

**RESULTS:** Final diagnoses revealed 11 malignant and 40 benign nodules. Only in two cases ultrasound demonstrated signs useful for a differential diagnosis (intrinsic microcalcifications). Correct differentiation of malignant from benign nodules was obtained by elastosonography in 43 / 51 cases with 5 false positives (FP) and 3 false negatives (FN). Specificity, sensitivity and accuracy were 87.5 %, 81.8 % and 86.2 %, respectively. Predictive negative value (PNV) and predictive positive value (PPV) were 94.5 % and 64 % area under the curve (AUC) 0.86.

**CONCLUSION:** Elastosonography provides an interesting contribution to the differentiation of malignant and benign thyroid nodules. Particularly worthy of mention is that an entirely elastic nodule pattern was observed only in relation to benign nodules, a result which would suggest that immediate recourse to FNAB might be avoided.

*Ultraschall Med. 2009 Apr;30(2):175-9.*

---

## **INTEROBSERVER AGREEMENT AT THE MALIGNANT THYROID NODULES WITH CONVENTIONAL ULTRASOUND (US) AND US ELASTOGRAPHY: PROSPECTIVE STUDY**

S. Park; Incheon/KR

**Purpose:** To investigate interobserver agreement at the malignant thyroid nodules with conventional B-mode US and real-time free hand US elastography.

**Methods and Materials:** Between December 2007 and February 2008, 42 patients (19-73 years; 45.0± 12.2 years) with 52 thyroid nodules were examined with conventional B-mode US and real-time free hand US elastography. All the patients were scheduled to undergo thyroid surgery due to thyroid nodule having been proven to be malignant on aspiration cytology. Three experienced, board certified radiologists independently performed conventional US and elastography and analyzed US images. Analysis in conventional US included composition (solid, cyst, mixed-echoic, sponge), nodular echogenicity (hyperechoic, isoechoic, hypoechoic, marked hypoechoic), margin (well-circumscribed, microlobulated or irregular), calcification (micro, macro, negative, mixed), shape (parallel, non-parallel) and final assessment (cyst, probably benign, low suspicious, suspicious). Ueno classification and odds ratio were made by using US elastography. Interobserver agreement was evaluated with Spearman correlation analysis except the area ratio (using Pearson correlation analysis).

**Results:** Statistically significant ( $p < .05$ ) concordance between 3 radiologists was found for most US features except for nodular echogenicity and margin of thyroid nodules on conventional US. The highest value of concordance was achieved in composition, followed by underlying parenchymal echogenicity, shape, calcification and final assessment. The least concordant finding was margin and nodular echogenicity on conventional US. However, there was no statistically significant concordance in Ueno classification and area ratio on elastography.

**Conclusion:** Conventional US made statistically significant concordance between radiologists in most of US features; however, US elastography did not make reliable interobserver agreement at malignant thyroid nodule.

*European Congress of Radiology, March 6 – 9<sup>th</sup>, 2009, Vienna, Austria*

---

## **THYROID NODULE EVALUATION WITH GRAYSCALE ULTRASOUND, COLOR DOPPLER, AND ELASTOGRAPHY: AN INTERNATIONAL MULTICENTER TRIAL**

Rick Feld (co-author F Flemming)

### **PURPOSE**

To determine if the combination of grayscale ultrasound imaging (US), color Doppler imaging (CDI) and Elastography can improve the characterization of thyroid nodules as benign or malignant.

### **METHOD AND MATERIALS**

Patients from two different institutions, one in the United States and one in Japan, scheduled either for fine needle biopsy or surgery of a suspicious thyroid nodule were evaluated with US, CDI and Elastography. All examinations were performed on an EUB-8500 scanner (Hitachi Medical Corporation, Tokyo, Japan). A total of 100 nodules were evaluated, 50 from each institution. Still images and video clips were digitally recorded for interpretation by 4 independent, experienced, blinded readers. Each nodule was graded in random order, by all 4 readers, on a 5 point scale (definitely benign to definitely malignant), based on each US mode separately and then based on all three US modes, combined. Based on final pathology, sensitivities, specificities, and accuracies were calculated and compared, using receiver operating characteristics (ROC) analysis and McNemar's test for correlated proportions.

### **RESULTS**

Pathology proved 81 benign nodules and 19 malignancies. When comparing the results of each reader, for one reader, the highest accuracy was achieved with Elastography, 77%, and with all three modes combined, 83%, which was significant ( $p=0.005$ ), however for the other three readers, there was no significant difference in the three modes. When comparing the results of each mode, one reader achieved highest accuracy with color Doppler (90%), which was significant ( $p<0.002$ ), one reader was more

accurate than the other readers in gray scale (89%) ( $p=0.002$ ), three readers were more accurate than the fourth in Elastography ( $p<0.05$ ), and two readers were more accurate than a third using all three modes ( $p<0.01$ ).

#### CONCLUSION

A combination of gray scale ultrasound, color Doppler imaging and Elastography has the potential to improve the characterization of thyroid nodules as benign or malignant. However, there remains high inter-observer variability. More research if necessary to determine the ultimate utility of Elastography.

#### CLINICAL RELEVANCE/APPLICATION

Characterization of thyroid nodule as benign or malignant in order to determine the necessity to proceed with biopsy.

*Radiological Society of North America 94<sup>th</sup> Scientific Assembly and Annual Meeting November 30<sup>th</sup> – December 5<sup>th</sup>, 2008, Chicago, USA*

---

### **THE ULTRASOUND ELASTOGRAPHY FOR THE INDETERMINATE THYROID NODULES IN CONVENTIONAL ULTRASOUND**

Jeong Seon Park

#### PURPOSE

To determine the usefulness of real-time freehand US Elastography to differentiate malignant from indeterminate thyroid nodules in conventional US (CUS), with pathologic diagnosis as the reference standard

#### METHOD AND MATERIALS

Between Oct. 2007 and Jan. 2008, conventional ultrasonography (CUS) in 78 thyroid nodules (61 benign; 17 malignant) of 56 patients (F: M=71: 7, mean age of 50.2 years) who were scheduled to undergo thyroidectomy showed indeterminate findings; no malignant sign (taller shape, speculated margin, calcification except rim-type, markedly hypoechoic), and not-definite benign (cyst or predominantly cystic nodule). The elasticity image was obtained with light compression and the elasticity score (1-5) according to the degree and distribution of strain. The proportion of no strain (PNS) per each nodule was assessed. Mean E scores and proportion of NS in benign and malignant nodules were examined by using a Student t-test. We evaluated the diagnostic performance to differentiate malignancy from benign lesions by using a receiver operating characteristic analysis to compare the area under the curve, sensitivity, specificity and accuracy at the cut-off value.

#### RESULTS

For E score, the mean + standard deviation was 2.9 + 0.8 for malignant lesions and 2.0 + 0.5 for benign lesions ( $P<.001$ ). For PNS, the mean + standard deviation was 63.2 + 27.8 for malignant lesions and 21.0 + 20.4 for benign lesions ( $P<.001$ ). The area under the curve of E score and PNS was 0.814 and 0.884. There was no significant difference of AUC between E score and PNS ( $p=0.143$ ). Sensitivity, specificity, and accuracy of E score at the cut-off value between 2 and 3 were 70.6%, 85.2%, and 76.0%, respectively. Those of PNS at the cut off value of 20% were 88.2%, 77.0%, and 78.2%, respectively.

#### CONCLUSION

For the differential diagnosis of indeterminate thyroid nodules in CUS, US Elastography would be valuable.

#### CLINICAL RELEVANCE/APPLICATION

For the thyroid nodules with indeterminate findings of CUS for, US Elastography may be useful as an adjunctive method to further categorize the nodules.

*Radiological Society of North America 94<sup>th</sup> Scientific Assembly and Annual Meeting November 30<sup>th</sup> – December 5<sup>th</sup>, 2008, Chicago, USA*

## ULTRASOUND ELASTOGRAPHY SHOWS POTENTIAL IN THYROID NODULES

By Erik L. Ridley

AuntMinnie staff writer

February 11, 2009

Ultrasound elastography may be useful as an adjunct for the challenging task of evaluating thyroid nodules, according to a pair of recent studies.

In the first study, a multicenter trial concluded that combining elastography with grayscale ultrasound and color Doppler offers the potential of improving the characterization of thyroid nodules. Meanwhile, a separate Korean study also determined that elastography was useful in providing differential diagnosis of indeterminate thyroid nodules.

"We've got a ways to go, but I think there's promise on the horizon for this rather vexing topic," said Dr. Rick Feld of Thomas Jefferson University (TJU) in Philadelphia. He presented the research during a talk at the 2008 RSNA meeting in Chicago.

Seeking to determine if the combination of the three ultrasound techniques could improve the characterization of thyroid nodules as benign or malignant, a research team led by Feld studied 100 nodules from patients scheduled for fine-needle biopsy or surgery of a suspicious thyroid nodule. Fifty nodules were contributed by TJU, while fifty were from a Japanese institution. Of the 100 nodules, pathology indicated that 81 were benign and 19 were malignant.

All three ultrasound techniques were performed using an EUB-8500 ultrasound scanner ([Hitachi Medical](#), Tokyo). Still images and video from each examination were digitally recorded and interpreted by four independent, experienced, and blinded readers.

The readers rated each nodule in random order on a five-point scale ranging from definitely benign to definitely malignant. The accuracy of each reader was measured first based on their use of each ultrasound mode alone, then on a combination of all three, according to Feld.

In the combination analysis, two readers were more accurate than a third reader using all three modes ( $p < 0.01$ ).

In analyzing the data by reader, one reader achieved their highest accuracy with elastography (77%) among the individual modes as well as with all three modes combined (83%), Feld said.

In analyzing the data by mode, one reader achieved the highest accuracy with color Doppler (90%), a difference that was statistically significant ( $p < 0.002$ ). One reader was more accurate than the other readers in grayscale (89%) ( $p = 0.002$ ), while three readers were more accurate than the fourth in elastography ( $p < 0.05$ ).

In examining reader variability, elastography produced the highest intraclass coefficient (0.44-0.63), representing a higher level of agreement among readers. Color Doppler had the lowest level of reader agreement (intraclass coefficient of 0.22-0.48), while grayscale ultrasound occupied the middle ground (intraclass coefficient of 0.32-0.53).

"There is interobserver variability in all three [methods], but it turns out that elastography did the best of all three," Feld said. "With all three combined, [interobserver variability was lower] than each of the three alone."

More research is warranted to determine the ultimate clinical utility of elastography when used in combination with other modalities, he said.

In a related presentation at the 2008 RSNA meeting, researchers from Hanyang University Hospital in Seoul, South Korea, found ultrasound elastography to be useful as an adjunctive method for categorizing indeterminate thyroid nodules.

The Hanyang research team prospectively studied 56 consecutive patients with 78 thyroid nodules (61 benign, 17 malignant) between October 2007 and January 2008. All patients were scheduled to undergo thyroidectomy and had indeterminate findings on conventional ultrasound.

Indeterminate findings included no malignant signs (taller shape, spiculated margin, calcification except rim type, and markedly hypoechoic) and the lack of definitely benign signs (cyst or predominantly cystic nodule), according to presenter Dr. Jeong-Seon Park.

Elasticity images were obtained with light compression, and an elasticity (E) score was calculated based on the Tsukuba Elasticity Score of 1 to 5 according to the degree and distribution of tissue strain, Park said. The proportion of no strain (PNS) was also assessed.

The researchers then examined the mean E scores and PNS in benign and malignant nodules using a Student's t-test. The technique's ability to differentiate malignant from benign nodules was evaluated utilizing a receiver operator characteristics (ROC) analysis to compare the area under the curve (AUC), sensitivity, specificity, and accuracy, according to Park.

	Benign lesions	Malignant lesions
<b>Mean E score</b>	2.0 ± 0.5	2.9 ± 0.8
<b>Mean PNS</b>	21.0 ± 20.4	63.2 ± 27.8

The differences in mean E score and mean PNS were statistically significant ( $p < 0.001$ ). The AUC was 0.814 for E score and 0.884 for PNS. The researchers found no statistically significant difference in the AUC between E score and PNS ( $p = 0.143$ ).

The E score between 2 and 3 led to a sensitivity of 70.6%, specificity of 85.2%, and accuracy of 76%, according to the researchers. Analyzing lesions using the PNS measurement yielded a sensitivity of 70.6%, specificity of 85.2%, and accuracy of 78.2%

"Although thyroid nodules had indeterminate findings in conventional ultrasound, the elasticity was significantly different between malignant and benign nodules," Park said.

## **THYROID US AND ELASTOGRAPHY USING CAROTID ARTERY PULSATION: UTILITY OF A COMBINED APPROACH IN DIAGNOSIS AND MANAGEMENT**

Manjiri Dighe

### **PURPOSE**

To compare accuracy of ultrasound and Elastography of the thyroid using carotid artery pulsation as the compression source in diagnosis and management of thyroid nodules.

### **METHOD AND MATERIALS**

A IRB approved study was conducted at the University of Washington comparing the thyroid ultrasound to Elastography. 59 patients scheduled for an ultrasound-guided FNA had participated in the study. Ultrasound was performed on IU-22 (Philips, Bothell, WA) machines and Elastography was performed on Hitachi EUB - 5500 machine prior to the FNA. Strain images were generated off-line and then compared with the FNA results. A quantitative thyroid stiffness index (TSI) was computed as follows:  $TSI = \text{Strain near carotid artery} / \text{Lowest strain in the thyroid nodule}$ . The ultrasound images were retrospectively reviewed by two experienced reviewers who were blinded to the final FNA results. The ultrasound images were scored from 1 to 5 based on preset parameters with increasing suspicion of malignancy. The reviewers were asked to suggest either FNA or follow up based on the imaging characteristics and Society of Radiologists in Ultrasound guidelines.

### **RESULTS**

TSI for papillary carcinoma was higher than other lesions ( $p=0.02$ ). There was significant discordance between the diagnosis and grade given by the ultrasound features between the reviewers as well as between the suggestions given by the reviewers. Using Elastography TSI, only there was a good concordance with the FNA diagnosis. Results are as follows: Concordance in diagnosis for reviewer 1 - 64%, Concordance in diagnosis for reviewer 2 - 55%, Discordance in diagnosis between reviewers - 33.33%, Discordance in suggestion (FU or FNA) - 35.2%, TSI concordance with diagnosis using a cut-off of 18 - 77.7%, Decrease in the number of FNAs on using a combined approach - 37%, Accuracy on using a combined approach compared to only ultrasound appearance to suggest FNA - 79.6%.

### **CONCLUSION**

Our study results indicate Elastography by pulsation of the carotid artery can serve as a repeatable and operator-independent compression source for thyroid Elastography. A combined approach of using the ultrasound features and Elastography decreased the number of FNA procedures and increased the accuracy.

### **CLINICAL RELEVANCE/APPLICATION**

A combined approach of using ultrasound features and Elastography could potentially decrease the number of thyroid FNAs as well as increase the accuracy in diagnosis.

*Radiological Society of North America 94<sup>th</sup> Scientific Assembly and Annual Meeting November 30<sup>th</sup> – December 5<sup>th</sup>, 2008, Chicago, USA*

## **ULTRASOUND ELASTOGRAPHY FEATURES OF MAJOR SALIVARY GLAND TUMORS**

Dana Dimitriu

### **PURPOSE**

Elastography is increasingly used in diagnosing tumors of the breast, thyroid gland or prostate. The aim of this ongoing study is to assess whether or not Elastography is helpful in increasing the diagnostic specificity of imaging in salivary gland tumors, since it has been proven that 2D and Doppler US, CT and even MRI are not very specific in this pathology.

### **METHOD AND MATERIALS**

Over the course of the last year, 23 patients with a total of 25 salivary gland lesions were examined. All patients presented with enlargement of one or more salivary glands; 22 of these presented with enlargement of the parotid region and one with enlargement of the submandibular region. The examination of each patient included grey-scale and Doppler ultrasound, followed by the elastographic examination, using the same specific protocol, developed in our department, for each patient. The elastographic appearance of the tumor was correlated with the pathology report, after surgical excision of the lesion.

### **RESULTS**

Most of the tumors in the study group were benign: pleomorphic adenomas (the most frequent salivary gland tumors) and Warthin tumors. The elastographic aspect for both of these tumors was most frequently that of lesions with heterogeneous elasticity, but never that of overall rigidity. The stiffest areas were located in the periphery of the tumor in pleomorphic adenomas. Warthin's tumors did not have any typical elastographic features in comparison to pleomorphic adenomas. Malignant tumors presented more extensive areas of increased tissue stiffness; extension of the stiffness beyond the grey-scale border of the tumor was noted in several cases, but it is yet unclear whether this might be considered a feature of malignancy, as in the case of breast cancer.

### **CONCLUSION**

Overall, the elastographic appearance of salivary gland tumors does not seem to fit into a definite pattern, such as the ones already described for breast tumors. So far, it is unlikely that Elastography might help in establishing the differential diagnosis between the various histological types of salivary gland tumor. However, it may raise the suspicion of malignancy in cases where the 2D image is inconclusive or falsely reassuring.

### **CLINICAL RELEVANCE/APPLICATION**

Combining Elastography with 2D and Doppler ultrasound might improve the specificity of imaging in salivary gland tumors; a correct pre-operative diagnosis helps determine the best surgical approach.

*Radiological Society of North America 94<sup>th</sup> Scientific Assembly and Annual Meeting November 30<sup>th</sup> – December 5<sup>th</sup>, 2008, Chicago, USA*

---

## **CLINICAL APPLICATION OF ULTRASOUND (US) ELASTOGRAPHY IN THYROID NODULES**

Jeong Seon Park

### **PURPOSE**

To evaluate the diagnostic performance of real-time freehand US Elastography in differentiating malignant from benign thyroid nodules, with pathologic diagnosis as the reference standard

### **METHOD AND MATERIALS**

Between Oct. 2007 and Feb. 2008, conventional ultrasonography (CUS) and real-time US Elastography were performed in 226 thyroid nodules of 128 patients who were scheduled to undergo thyroidectomy. We excluded 23 lesions because of poor quality of strain images. Finally, 203 thyroid nodules (117 malignant; 86 benign) of 114 patients (F: M=101:13, mean age of 47.8 years) were included. According to the findings of grey-scale US, the result of CUS were divided into three

categories; benign, indeterminate, and malignancy. The elasticity (E) score was assigned from 1 to 5 according to the degree and distribution of strain induced by light compression. The proportion of no strain (PNS, %) per each nodule was assessed. Mean E scores and PNS were examined by using a Student t-test. We evaluated the diagnostic performance to differentiate malignancy from benign lesions by using a ROC analysis to compare the area under the curve, sensitivity, specificity and accuracy at the optimal cut-off value.

## RESULTS

For E score, the mean + standard deviation was 3.7 + 1.0 for malignant lesions and 2.0 + 0.7 for benign lesions ( $P < .001$ ). For PNS, the mean + standard deviation was 82.3 + 24.4 for malignant lesions and 23.3 + 23.6 for benign lesions ( $P < .001$ ). The area under the curve of CUS, E score and PNS was 0.864, 0.899, and 0.936, respectively. The AUC of PNS was significantly higher than CUS ( $p = .004$ ) or E score ( $p = .004$ ). There was no significant difference of AUC between CUS and E score ( $p = 0.181$ ). Sensitivity, specificity, and accuracy of CUS at the cut-off value between indeterminate and malignancy were 83.6%, 86.0%, and 84.6%, respectively. Those of E score at the cut-off value between 2 and 3 were 88.8%, 79.1%, and 82.5%, respectively. Those of PNS at the cut off value of 50% were 87.1%, 88.4%, and 87.5%, respectively.

## CONCLUSION

For the differential diagnosis of thyroid nodules, the diagnostic performance of elasticity score or the proportion of no strain area had at least equivalent value compared to CUS.

## CLINICAL RELEVANCE/APPLICATION

For the differentiation of malignant thyroid nodules from benign lesions, US Elastography may be useful as an adjunctive method.

*Radiological Society of North America 94<sup>th</sup> Scientific Assembly and Annual Meeting November 30<sup>th</sup> – December 5<sup>th</sup>, 2008, Chicago, USA*

---

## SONOELASTOGRAPHY OF SUPERFICIAL LYMPH NODE ENLARGEMENT: BENIGN VS. MALIGNANT

Botar-Jid C<sup>1</sup>, Fodor D<sup>2</sup>, Ducea SM<sup>1</sup>, Ciurea A<sup>1</sup>, Papita A<sup>2</sup>, Vasilescu D<sup>1</sup>

<sup>1</sup>Radiology Department, Iuliu Hatieganu University of Medicine and Pharmacy Cluj-Napoca; <sup>2</sup>2nd Medical Clinic, Iuliu Hatieganu University of Medicine and Pharmacy Cluj-Napoca

**Aim:** The aim of the study is to assess the diagnostic role of sonoelastography in differentiating benign from malignant superficial lymph nodes.

**Method:** The study group included 35 patients examined between May 2007 - January 2008. All patients presented palpable cervical, supraclavicular, axillary and/or inguinal lymph nodes. Total of 48 lymph nodes were assessed. Ultrasonography (US) was carried out with a Hitachi EUB 8500 equipment. Gray-scale US, power Doppler and sonoelastography was performed in each patient. Standardized acquisition parameters were used during the elastographic examination. The elastographic appearance of the lymph nodes was assessed qualitatively based on a five type scale used in breast diagnosis. For qualitative elasticity expression, the muscle-to-lymph nodes strain ratio index was computed. The final diagnosis was established based on biopsy, pathological results or follow-up.

**Results:** Benign lymph nodes presented a soft appearance (type 1 and 2). The moderate rigid appearance (type 3) and the stiff pattern (type 4 and 5) were encountered in malignant lymph nodes (lymphoma and metastatic lymph nodes from laryngeal, parotid, breast and rectal tumor). The muscle-to-lymph nodes strain ratio index has low values (0.12 - 1.11) in inflammatory lymph nodes. An intermediate muscle-to-lymph nodes strain ratio index was encountered in Hodgkin lymphoma (1.55-1.91) and non Hodgkin lymphoma (2.21 - 3.54 in), respectively. The muscle-to-lymph nodes strain ratio index has higher values in metastatic lymph nodes (2.60 - 13.24).

**Conclusion:** Sonoelastography represents a new and promising imaging method for the better characterization and differentiation of superficial lymph nodes.

*XXth Congress of European Federation of Societies for Ultrasound in Medicine and Biology/XIth Romanian Conference of Ultrasound in medicine and Biology, May 31 – June 3 2008, Timisoara, Romania. (Ultraschall in Med, 2008, suppl 1, OP15.5)*

---

## **US-ELASTOGRAPHY IN THE DIFFERENTIAL DIAGNOSIS OF BENIGN AND MALIGNANT THYROID NODULES.**

Asteria C, Giovanardi A, Pizzocaro A, Cozzaglio L, Morabito A, Somalvico F, Zoppo A.

Department of Experimental Endocrinology and Cardiovascular Prevention, Policlinico MultiMedica, IRCCS, Milan, Sesto San Giovanni, Italy.

**BACKGROUND:** Ultrasound (US)-elastography is a newly developed imaging technique for the reconstruction of tissue stiffness by measuring the degree of tissue's deformation in response to the application of an external force. This technique has previously been shown to be useful in the differential diagnosis between benign and malignant tumors.

**METHODS:** The objective of this study was to assess the diagnostic accuracy of US-elastography in the differential diagnosis of thyroid cancer, using the cytologic/histopathologic analysis as the reference standard. A total of 67 consecutive patients with thyroid nodules who were referred to the Thyroid Unit at the Policlinico MultiMedica were enrolled in this prospective study between January and December 2006. Eighty-six nodules in these patients were examined by US B-mode, US color-power-Doppler, and US-elastography. Nodules were subjected to fine-needle aspiration biopsy and patients with a reading of malignant or indeterminate had thyroid surgery. The final diagnosis was based on the cytology reading in those who did not have surgery and the histopathology reading in those who had surgery. US-elastography scores were based on four classes of tissue stiffness (class 1 for soft nodules; class 2 and 3 for nodules with an intermediate degree of stiffness; class 4 for anelastic lesions).

**RESULTS:** Seventeen nodules were malignant and 69 were benign. Sensitivity and specificity of the US-elastography for thyroid cancer diagnosis were 94.1% (16/17) and 81% (56/69), respectively. The positive and negative predictive values were 55.2% (16/29) and 98.2% (56/57), respectively. The accuracy of the technique was 83.7%.

**CONCLUSION:** US-elastography is a promising technique that, combined with other US modalities, is easy and rapid to perform and can help to identify thyroid nodules that are likely to be malignant. An important limitation is probably lack of sensitivity for follicular thyroid carcinoma.

*Thyroid. 2008 May;18(5):523-31.*

---

## **ULTRASOUND ELASTOGRAPHY QUICKLY IDENTIFIES MALIGNANT THYROID NODULES**

Diagnostic Imaging, May 19, 2008

by Wendy Despain

Ultrasound elastography provides an accurate diagnosis for malignant thyroid nodules about eight out of 10 times, according to Italian researchers. Elastography has previously shown promise in the diagnosis of breast and prostate cancers.

Dr. Carmela Asteria and colleagues at the Policlinico MultiMedica, IRCCS, in Milan published their research in the May 1 issue of *Thyroid*. They studied 67 consecutive patients referred to their practice between January and December of 2006.

The researchers examined each patient using B-mode ultrasound, color power Doppler ultrasound, and ultrasound elastography. A total of 86 nodules were identified and tested with fine-needle aspiration biopsy. Those nodules identified as malignant or indeterminate by biopsy were removed in surgery, and histological findings after surgery showed 17 were malignant.

The investigators compared the surgical and biopsy findings with the ultrasound elastography results and found the technique had a positive predictive value of 55.2% and negative predictive value of 98.2%. Sensitivity was 94.1%, and specificity was 81%. It was considered 83.7% accurate.

The researchers concluded that ultrasound elastography is a promising diagnostic tool for quickly and easily identifying malignant thyroid nodules, although they noted a lack of sensitivity for follicular thyroid carcinoma.

---

## **ELASTOSONOGRAPHY OF THYROID LESIONS**

[Article in French]

Tranquart F, Bleuzen A, Pierre-Renoult P, Chabrolle C, Sam Giao M, Lecomte P.

Service d'Ultrasons, CHRU Tours, Hôpital Bretonneau, 37044 Tours Cedex 1. [tranquart@med.univ-tours.fr](mailto:tranquart@med.univ-tours.fr)

While ultrasound is the imaging modality of choice for diagnosis of thyroid lesions, characterization remains limited and tissue diagnosis frequently is required for management. The availability of additional tools such as elastography may improve lesion characterization and direct management.

**MATERIALS AND METHODS:** A total of 96 patients (11 males and 85 females; 58+/-24 years) referred for fine needle aspiration (FNA) of mainly solid thyroid nodules 9-32 mm in diameter underwent conventional US and elastosonography. Results on elastography were correlated with histological results from FNA and classified as follows: suspected malignant lesion, suspected benign lesion, suspicious, indeterminate.

**RESULTS:** The nodules were classified as follows: 95 nodules were soft (classes I and II) and 13 nodules were hard (classes III and IV). No cancers were detected in class I and II lesions and 6 cancers were detected in class III and IV lesions. FNA provided insufficient cellular material for diagnosis in 5 class I-II nodules and 2 class III-IV nodules.

**CONCLUSION:** Real-time elastosonography may be a useful adjunct to conventional US in the evaluation and characterization of thyroid nodules allowing identification of patients at high risk of malignancy for whom tissue diagnosis and/or close follow-up is required.

*J Radiol. 2008 Jan;89(1 Pt 1):35-9.*

---

## **ULTRASOUND ELASTOGRAPHY IN THYROID CARCINOMA: WHAT IS ITS RELEVANCE?**

Presenter: Rahul Dharmadhikari

Co-authors: David Richardson, Sarah Johnson  
Newcastle Royal Infirmary, UK

**Purpose:** Assessing accuracy of Ultrasound Elastography to differentiate benign from malignant thyroid tumours.

**Materials and Methods:** The study involved 30 patients who underwent thyroid ultrasound Elastography and biopsy at our institution from May 2005 to June 2006. Real time Elastography was performed using Hitachi EUB-8500 with a 6-13 MHz linear array probe. The Elastography patterns were colour coded depending on appearances using a preset colour code as hard, mixed and soft. Biopsies were taken from one/two sites and sent for cytology and positive specimens for subsequent histology. The results were correlated to determine accuracy of the procedure.

**Results:**

The 30 patients involved in the study had 34 biopsies. 22 biopsies were classified as soft or diffusely soft nodules. 6 had mixed Elastography appearances and 6 patients had a hard nodule on Elastography. Total 2 cancers were confirmed on histology both of which were in hard nodules. Of the 34 biopsies, 6 (18%) were hard on Elastography, but 100% of the cancers were found in hard nodules

**Conclusions:**

Elastography works on the principle that malignant lesions are harder than benign lesions as 100% malignancies were found in hard nodules, if a nodule is soft on Elastography the the indication for a biopsy is questionable. Also in a multinodular goitre Elastography can be used to target a particular nodule for biopsy which is hard on Elastography

**Clinical Relevance/Application:**

If further studies validate these findings, there will be a significant reduction in the number of thyroid biopsies performed and a massive increase in the yield from the performed biopsies.

*Radiological Society of North America 93<sup>rd</sup> Scientific Assembly and Annual Meeting November 25<sup>th</sup> – 30<sup>th</sup>, 2007, Chicago, USA*

---

**CLINICAL EVALUATION OF ELASTOGRAPHY FOR THE DIFFERENTIAL DIAGNOSIS OF THYROID FOLLICULAR TUMORS**

N. Fukunari<sup>1</sup>, K. Arai<sup>1</sup>, A. Nakamura<sup>1</sup>, S. Sakaue<sup>1</sup>, T. Mitake<sup>2</sup>; <sup>1</sup>Yokohama/JP, <sup>2</sup>Chiba/JP

**Purpose:** The diagnosis and management of follicular cancer of the thyroid gland remains a controversial topic. The aim of this study was to evaluate the clinical usefulness of elastography imaging for the differential diagnosis of thyroid follicular lesions.

**Methods and Materials:** 88 follicular tumors were examined by elastography. The images of thyroid follicular lesions were recognized as four typical patterns as follows: Pattern 1 - nodule is relatively homogenous and colored with light green. Pattern 2 - the center of nodule is colored with green and its periphery is colored with blue. Pattern 3 - nodule is mixed-colored with light green and red. Pattern 4 - the whole tumor is hard and displayed in blue.

**Results:** All the follicular tumors were surgically and histopathologically diagnosed finally. In this series, 44 hyperplastic nodules, 28 follicular adenomas and 16 follicular cancers were found. Of the 72 benign thyroid nodules, 60 cases demonstrated Pattern 1, 3 cases Pattern 2 and 9 cases Pattern 3. Of the 16 follicular cancers, on the other hand, 1 case was Pattern 1, 14 cases Pattern 2, and 1 case Pattern 3.

**Conclusion:** In follicular cancers, the major elastography pattern was Pattern 2. Assuming Pattern 2 to be malignant and others to be benign, 69 of 72 benign tumors and 14 of 16 follicular cancers were accurately diagnosed, yielding a sensitivity of 87.5%, a specificity of 95.3%, and an accuracy of 94.3%. Elastography can provide new useful information for the differential diagnosis of thyroid follicular tumors.

*Radiological Society of North America 93<sup>rd</sup> Scientific Assembly and Annual Meeting November 25<sup>th</sup> – 30<sup>th</sup>, 2007, Chicago, USA*

---

**ELASTOGRAPHY: NEW DEVELOPMENTS IN ULTRASOUND FOR PREDICTING MALIGNANCY IN THYROID NODULES.**

Rago T, Santini F, Scutari M, Pinchera A, Vitti P. (Department of Endocrinology University of Pisa.)

**Background:** Elastography is a newly developed dynamic technique that employs ultrasound (US) to provide an estimation of tissue stiffness by measuring the degree of distortion under the application of an external force. US elastography has been applied to differentiate malignant from benign lesions.

**Patients:** This study included 92 consecutive patients with a single thyroid nodule who underwent surgery for compressive symptoms or suspicion of malignancy on fine needle aspiration (FNA) cytology. Tissue stiffness on US elastography was scored from 1 (greatest elastic strain) to 5 (no strain).

**Results:** On US elastography score 1 and 2 were found in 49 cases, all benign lesions; score 3 in 13 cases, 1 carcinoma and 12 benign lesions; score 4 and 5 in 30 cases, all carcinomas. Thus, the elasticity scores 4-5 were highly predictive of malignancy ( $p < 0,0001$ ) with a sensitivity of 97%, a specificity of 100%, a positive predictive value of 100% and a negative predictive value of 98%. In 32 patients with an indeterminate FNA result the conventional US was not predictive of malignancy, while an US elastographic score 4-5 was observed in 6/7 (86%) patients with carcinoma on histology, and score 1-3 in all the 25 patients with benign lesions.

**Conclusion:** US elastography has great potential as an adjunctive tool for the diagnosis of thyroid cancer, especially in indeterminate nodules on cytology. Larger prospective studies are needed to confirm these results and to establish the diagnostic accuracy of this new technique.

*J Clin Endocrinol Metab.* 2007 Aug;92(8):2917-22

---

## **ULTRASOUND HELPS SPOT MALIGNANT THYROID NODULES**

NEW YORK (Reuters Health), Sep 12, 2007

Ultrasound elastography shows promise in predicting malignancy in thyroid nodules, according to Italian researchers.

In the August issue of the *Journal of Clinical Endocrinology and Metabolism*, Dr. Paolo Vitti and colleagues at the University of Pisa note that such nodules are common, and the great majority are benign. Fewer than 5% are malignant.

Firmer nodules are associated with an increased risk of malignancy, they add, but this "is highly subjective and dependent on the experience of the examiner."

To evaluate the efficacy of ultrasound elastography in determining tissue stiffness and hence the risk of malignancy, the researchers employed the approach in 92 patients.

All underwent surgery because of compressive symptoms or suspicion of malignancy following fine needle aspiration (FNA) cytology. Thirty-one of the patients (34%) had a final diagnosis of malignancy on histology.

Employing a five-point scale, which rated 1 as the greatest elasticity and 5 as the least, 49 patients with benign lesions had a score of 1 or 2.

Only one of the 13 patients with a score of 3 had cancer, but this was true of all of the remaining 30 patients who had a score of 4 or 5.

Thus, say the investigators, scores of 4 or 5 were highly predictive of malignancy and gave a sensitivity of 97% and a specificity of 100%.

In 32 patients in whom FNA gave indeterminate results, conventional ultrasound was not predictive of malignancy. However, elastography gave a score of 4 or 5 in seven of the eight patients with malignancy, and a score of 3 or less in the remaining 25 patients with benign lesions.

The researchers call for further studies, but conclude that "ultrasound elastography seems to have great potential as a new tool for the diagnosis of thyroid cancer, especially in nodules with indeterminate cytology."

By David Douglas

(J Clin Endocrinol Metab 2007;92:2917-2922.)

---

### **EFFICIENCY OF ULTRASONIC ELASTOGRAPHY IN THE DIFFERENTIAL DIAGNOSIS (METASTATIC OR REACTIVE) OF THE ENLARGED CERVICAL LYMPH NODE**

F. Alam, K. Naito, T. Tachikake, J. Horiguchi, H. Fukuda, H. Yasutomi, N. Hirai, K. Marukawa, K. Ito; Hiroshima/JP

**Purpose:** Evaluation of ultrasonic elastographic appearance of enlarged cervical lymph nodes and exploration of the diagnostic reliability in differentiating between metastatic and reactive cervical lymphadenopathy.

**Methods and Materials:** Realtime elastography of 60 enlarged cervical lymph nodes (28 metastatic, 32 reactive) from 25 patients (16 men, 9 women; age range: 11-85 years; 14 head-neck cancer, 11 having no malignancies) was performed. All the lymph nodes were evaluated for distribution and the percentage of stiff areas. Then they were classified using a 5-pattern system (1-5). Pattern 1: Stiff areas occupying the whole or almost whole lymph node (LN) with or without a thin rim of peripheral relatively soft areas. Pattern 2: Same as pattern 1 with central relatively soft areas. Pattern 3: Stiff areas occupying more than 50% of the LN. Pattern 4: Stiff areas occupying not more than 50% of the LN. Pattern 5: Small stiff areas scattered into relatively soft area of the LN. The cutoff line for metastatic lesions was set between 3 and 4. Patterns 1 to 3 were considered malignant and 4 and 5 were considered reactive. Histopathological results and clinical findings (including CT findings) were considered as reference standard for analysis of elastographic findings.

**Results:** Sensitivity, specificity, positive predictive value, negative predictive value and accuracy were 78.6%, 100%, 100%, 84.2% and 90%, respectively.

**Conclusion:** Ultrasonic elastography showed excellent performance in the diagnosis of metastatic cervical lymphadenopathy. Due to high specificity of this method, invasive procedures might be reduced when ultrasonic elastographic result is positive for lymphnode metastasis.

*European Congress of Radiology, March 9<sup>th</sup> – 12<sup>th</sup> 2007, Vienna, Austria*

---

### **THYROID ELASTOGRAPHY USING CAROTID ARTERY PULSATION FOR DIFFERENTIAL DIAGNOSIS OF THYROID NODULES: PRELIMINARY RESULTS**

Dighe M, Bae U, Dubinsky T, Minoshima S, Kim Y, Washington USA

#### **PURPOSE**

To evaluate the feasibility of thyroid elastography using carotid artery pulsation as the compression source and investigate its potential in differential diagnosis of thyroid nodules.

#### **METHOD AND MATERIALS**

A pilot study is being conducted at the University of Washington. 22 patients scheduled for a thyroid FNA have so far participated in the study. In contrast to the conventional approach of using external compression in thyroid elastography, pulsation of the carotid artery was used as the compression source. Lateral expansion of the carotid artery during systole compresses the thyroid against the trachea and restores it to the original state during diastole. Baseband ultrasound data of thyroid nodules were acquired using a Hitachi EUB-5500 machine. Strain images were generated off-line and correlated with FNA results. The strain near the carotid artery indicates the amount of compression applied by carotid artery pulsation. A quantitative thyroid stiffness index (TSI) was computed as follows:  $TSI = \text{Strain near carotid artery} / \text{Lowest strain in a thyroid nodule}$ .

## RESULTS

For all cases, a thyroid nodule(s) can be distinguished from the surroundings in strain images. Strain variation within a nodule is often observed, indicating stiffness variation inside a nodule. TSI for papillary carcinoma was higher than other lesions, such as follicular neoplasm and nodular goiter, indicating that papillary carcinoma is stiffer than other lesions ( $p=0.02$ ). This finding is consistent with the in vitro stiffness measurements of thyroid lesions previously reported in the literature.

## CONCLUSION

Results indicate pulsation of the carotid artery can serve as a repeatable and operator-independent compression source for thyroid elastography. Thyroid elastography using carotid artery pulsation could potentially guide FNA by helping select lesions to be sampled in order to improve its sensitivity and specificity and/or reduce the number of insufficient cases. In addition, TSI may provide a quantitative measure of thyroid stiffness for differential diagnosis of thyroid nodules.

## CLINICAL RELEVANCE/APPLICATION

Thyroid elastography using carotid artery pulsation is an operator-independent method for non-invasive differential diagnosis of thyroid nodules.

*Radiological Society of North America 92<sup>nd</sup> Scientific Assembly and Annual Meeting November 26<sup>th</sup> – December 1<sup>st</sup>, 2006, Chicago, USA*

---

## CLINICAL EVALUATION OF REAL-TIME TISSUE ELASTOGRAPHY (RTE) FOR THE DIFFERENTIAL DIAGNOSIS OF THYROID FOLLICULAR LESIONS

N. Fukunari<sup>1</sup>, K. Tanaka<sup>2</sup>, K. Arai<sup>1</sup>, A. Nakamura<sup>1</sup>, K. Yamazaki<sup>1</sup>, K. Ito<sup>2</sup>, T. Mitake<sup>2</sup>; <sup>1</sup>Yokohama/JP, <sup>2</sup>Tokyo/JP

**Purpose:** The diagnosis and management of follicular carcinoma of the thyroid remains a controversial topic. The aim of this study was to evaluate the clinical usefulness of real-time tissue elastography (RTE) imaging for the differential diagnosis of thyroid follicular lesions.

**Methods and Materials:** The 56 follicular tumors obtained from 49 patients were examined by gray-scale US imaging, colour Doppler imaging and RTE. A comparative study of these images was made and final diagnosis was determined by histological diagnosis. The images of thyroid follicular lesions obtained by RTE were recognized as four typical patterns as follows: 1) nodule is relatively homogenous and colored with light green, 2) the centre of nodule is colored with green, and its periphery is colored with blue, 3) light green and red mixed inside blue zone and 4) the whole tumor is hard and displayed in blue.

**Results:** All the follicular tumors were cytologically and histopathologically confirmed. In this series, 30 adenomatous nodules, 21 follicular adenomas and 5 follicular cancers were found. Of the 51 benign thyroid nodules, 48 cases (94.1%) demonstrated pattern 1, and 3 cases demonstrated pattern 3. On the other hand, all the follicular cancer cases manifested as pattern 2.

**Conclusion:** In follicular cancer, the difference of elasticity from the core and the periphery of the tumor is supposed to be caused by the difference of hypercellularity. RTE can provide new useful information for the differential diagnosis of thyroid follicular lesions.

*European Congress of Radiology, March 3<sup>rd</sup> – 7<sup>th</sup> 2006, Vienna, Austria*

---

## EVALUATION OF THYROID MALIGNANCY USING REAL-TIME TISSUE ELASTOGRAPHY

K. Tanaka<sup>1</sup>, N. Fukunari<sup>2</sup>, T. Igarashi<sup>1</sup>, H. Akasu<sup>1</sup>, W. Kitagawa<sup>1</sup>, K. Shimizu<sup>1</sup>, K. Ito<sup>1</sup>; <sup>1</sup>Tokyo/JP, <sup>2</sup>Yokohama/JP

**Purpose:** The aim of this study was to investigate the improvement of differentiation between benign and malignant thyroid tumors by real-time tissue elastography (RTE).

**Methods and Materials:** Two hundred thyroid nodular lesions found on B-mode ultrasonography

were examined and evaluated using RTE (EUB-8500, HITACHI). All cases were also compared with the cytological and pathological results.

**Result:** Unique and characteristic images were obtained by RTE in every type of thyroid nodular disease. Images were mainly divided into four visual types; Pattern 1: colored light green throughout nodule, Pattern 2: colored light green in the center and blue peripherally, Pattern 3: blue zone at base with mixed coloring of light green and sometimes with red, Pattern 4: blue coloring throughout the nodule.

130 tumors were histologically diagnosed as malignancy and consisted of 80 tumors (61.5%) of pattern 4, 17 (13.1%) of pattern 3, 21 (16.2%) of pattern 2 and 12 (9.2%) of pattern 1. In papillary thyroid cancer, 87 of the 100 tumors (87.5%) showed pattern 3 or 4. Especially, lymph node metastasis demonstrated pattern 4. Eight of the 15 follicular cancer cases (53.3%) showed pattern 2.

**Conclusion:** In the differential diagnosis of thyroid nodules, RTE with simultaneous gray scale imaging provides useful information, especially in follicular tumor and papillary cancer diagnosis.

*European Congress of Radiology, March 3<sup>rd</sup> – 7<sup>th</sup> 2006, Vienna, Austria*

---

## **INITIAL EXPERIENCES IN THE USE OF 'ELASTOGRAPHY' IN THE ULTRASOUND ASSESSMENT OF THYROID NODULES**

Richardson DL, Newcastle

**Purpose:** 'Elastography' is a newly marketed feature available from Hitachi.

It measures the different elastic properties of tissues and displays them as a colour map. The aim of the study was to assess whether the additional information obtained helped in the differentiation of benign from malignant thyroid nodules and whether this could be used to direct better biopsies.

**Methods:** All patients in a 4-week period attending our hospital for thyroid ultrasound were examined by a single operator. Scans were performed initially without 'Elastography' and assessment of the likelihood of malignancy made and nodule chosen for biopsy. The 'Elastography' was then used and the additional information obtained used to give an assessment of malignancy and suggest a nodule for biopsy. Biopsies were then performed (of more than one nodule if necessary).

**Results:** Of the first 20 patients scanned there were 3 patients where the additional 'Elastography' information suggested that a different nodule should be biopsied or a particular part of a nodule should be targeted. The cytological reports are awaited. In the remaining 17 where a typical benign multinodular goitre was seen with conventional ultrasound, the 'Elastography' demonstrated 'soft' nodules giving an additional feature of benign disease.

**Conclusion:** In this preliminary study 'Elastography' helped in all patients: giving another sign of benign disease or by suggesting a more malignant appearing nodule for biopsy.

*British Medical Ultrasound Society Annual meeting, December 13<sup>th</sup> – 15<sup>th</sup>, 2005, Manchester, UK*

---

## **CLINICAL EVALUATION OF REAL-TIME TISSUE ELASTOGRAPHY (RTE) FOR THE DIFFERENTIAL DIAGNOSIS OF THYROID FOLLICULAR LESIONS.**

Nobuhiro Fukunari, Ito Hospital, Tokyo, JAPAN

**PURPOSE:** The diagnosis and management of follicular carcinoma of the thyroid gland remains a controversial topic. Fine needle aspiration, although very sensitive with other types of thyroid cancer, has limited accuracy with follicular lesions. Color-Doppler (CD) imaging has been expected for the differential diagnosis between follicular adenoma and follicular carcinoma, otherwise, the findings obtained by CD imaging could not easily be confirmed by cytological and pathological methods. The aim of this study was to evaluate the clinical usefulness of Real-time tissue elastography (RTE) imaging for the differential diagnosis of thyroid follicular lesions.

**METHOD AND MATERIALS:** The 56 follicular tumors obtained from 49 patients were examined by gray-scale US imaging, CD imaging and RTE. Fine needle aspiration cytology was performed in all lesions under US guidance and the site of needle insertion was decided by RTE. A comparative study of these images was made and final diagnosis was determined by the cytological and histological diagnosis. The images of thyroid follicular lesions obtained by RTE were recognized as four typical patterns as follows, Pattern 1 : nodule is relatively homogenous and colored with light green. Pattern 2 : the center of nodule is colored with green or sometimes with mix of light green and red. And its periphery is colored with blue. Pattern 3 : light green and red mixed inside blue zone. It shows tumor mixed with hard part and relative soft part. Pattern 4 : the whole tumor is hard and displayed in blue.

**RESULTS:** All the follicular tumor was cytologically and histopathologically diagnosed finally. In this series, 30 adenomatous nodules, 21 follicular adenomas and 5 follicular cancers were found. Of the 51 benign thyroid nodule, 48 cases (94.1%) demonstrated as Pattern 1, 3 cases demonstrated as Pattern 3. On the other hands, all the follicular cancer were recognized as Pattern 2.

**CONCLUSIONS:** In follicular cancer, the difference of elasticity from core of the tumor and periphery of the tumor is supposed to be caused by the difference of hypercellularity. RTE can provide new useful information for the differential diagnosis of thyroid follicular lesions.

*Radiological Society of North America 91<sup>st</sup> Scientific Assembly and Annual Meeting, November 27<sup>th</sup> – 30<sup>th</sup> 2005, Chicago, USA*

---

#### **CLINICAL EVALUATION OF THYROID TUMOR WITH REAL-TIME TISSUE ELASTOGRAPHY.**

*K Tanaka<sup>1</sup>, N Fukunari<sup>2</sup>, H Akasu<sup>1</sup>, W Kitagawa<sup>1</sup>, K Shimizu<sup>2</sup>, K Ito<sup>2</sup>, T Mitake<sup>3</sup>.*

<sup>1</sup>Department of Surgery, Nippon Medical School, Tokyo, JAPAN; <sup>2</sup>Ito Hospital, Tokyo, JAPAN;

<sup>3</sup>Hitachi Medical Corporation, Tokyo, JAPAN.

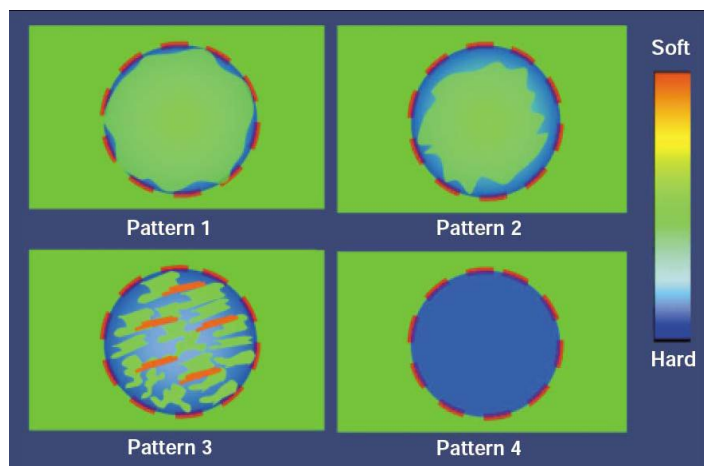
**Aims:** Various practical difficulties exist in realizing an objective technique for visualizing palpable thyroid tumors. In this study, we have explored the feasibility of using *Elastography* technique for the clinical evaluation of thyroid tumors. We will discuss the technique and the clinical outcome of this study.

**Methods:** Sixty cases with nodular lesions (40 papillary thyroid cancers, 8 follicular thyroid cancers, 12 adenomatous goiters, and 5 malignant lymphomas) found by ultrasound B-mode were examined and evaluated with the *Elastography* (EUB-8500, HITACHI, Japan). The results of *Elastography* were compared against the cytology, the cut section, the pathology, and with the images of computed tomography.

**Results:** Using *Elastography*, unique and characteristic images were obtained in every type of thyroid nodular disease. *Elastography* images were classified into 4 types: Pattern 1, light green throughout the inside of the nodule; Pattern 2, light green in the center and blue in the periphery of the nodule; Pattern 3, blue base with mixed colors of light green and red; and Pattern 4, blue in the entire nodule. (Figure 1) Papillary thyroid cancer images mainly showed Pattern 3 or 4, while lymph node metastasis specifically had the images of Pattern 4. Follicular thyroid cancer showed Pattern 2. Adenomatous goiter showed diffuse light green (Pattern 1).

**Conclusions:** *Elastography* provides new information for diagnosing thyroid tumors and helps with deciding therapy. In follicular lesions, it shows distinct differences in tissue elasticity between the peripheral zone and the center. It is possible to see the presence of lymph node metastasis in papillary thyroid cancer, yielding important information for clinical diagnosis. Thus, we believe that *Elastography* will help in creating treatment plans by providing new substantial clinical information.

Figure 1: Proposed Clarification of Elastography for Thyroid Tumors



*Fourth International Conference on the Ultrasonic Measurement and Imaging of Tissue Elasticity, October 16<sup>th</sup> – 19<sup>th</sup> 2005, Austin, Texas*

## **CLINICAL EVALUATION OF REAL-TIME TISSUE ELASTOGRAPHY (RTE) FOR THE DIFFERENTIAL DIAGNOSIS OF THYROID FOLLICULAR LESIONS.**

Nobuhiro Fukunari, Kumi Tanaka, Kiminori Sugino, Koichi Ito, Kunihiko Ito  
Diagnostic Imaging and Surgery, Ito hospital, Tokyo, Japan 150-8303, Nippon Medical School

### **PURPOSE**

The diagnosis and management of follicular carcinoma of the thyroid gland remains a controversial topic. Fine needle aspiration, although very sensitive with other types of thyroid cancer, has limited accuracy with follicular lesions. Color-Doppler (CD) imaging has been expected for the differential diagnosis between follicular adenoma and follicular carcinoma. The aim of this study was to evaluate the clinical usefulness of Real-time tissue Elastography (RTE) imaging for the differential diagnosis of thyroid follicular lesions.

### **METHOD AND MATERIALS**

The 56 follicular tumors obtained from 49 patients were examined by gray-scale US imaging, CD imaging and RTE. Fine needle aspiration cytology was performed in all lesions under US guidance and the site of needle insertion was decided by RTE. A comparative study of these images was made and final diagnosis was determined by the cytological and histological diagnosis. The images of thyroid follicular lesions obtained by RTE were recognized as four typical patterns as follows, Pattern 1: nodule is relatively homogenous and colored with light green. Pattern 2: the center of nodule is colored with green or sometimes with mix of light green and red. And its periphery is colored with blue. Pattern 3: light green and red mixed inside blue zone. It shows tumor mixed with hard part and relative soft part. Pattern 4: the whole tumor is hard and displayed in blue.

### **RESULTS**

All the follicular tumor was cytologically and histopathologically diagnosed finally. In this series, 30 adenomatous nodules, 21 follicular adenomas and 5 follicular cancers were found. Of the 51 benign thyroid nodule, 48 cases (94.1%) demonstrated as Pattern 1, 3 cases demonstrated as Pattern 3. On the other hands, all the follicular cancer was recognized as Pattern 2.

### **CONCLUSIONS**

In follicular cancer, the difference of elasticity from core of the tumor and periphery of the tumor is supposed to be caused by the difference of hypercellularity. RTE can provide new useful information for the differential diagnosis of thyroid follicular lesions.

*XVIII th Congress of European Federation of Societies for Ultrasound in Medicine and Biology, 25<sup>th</sup> – 27<sup>th</sup> September, 2005, Geneva, Switzerland*

---